

PROTOCOL FOR THE 18⁺⁰-20⁺⁶ WEEK ANOMALY SCAN

This guidance does not override the individual responsibility of health professionals to make appropriate decision according to the circumstances of the individual patient in consultation with the patient and /or carer. Health care professionals must be prepared to justify any deviation from this guidance.

INTRODUCTION

This is a joint protocol developed by the Radiology and Obstetrics Directorates.

The purpose of this protocol is to provide an agreed and accepted standard for foetal anomaly scanning within Worcestershire Acute Hospitals NHS Trust

The fetal anomaly scan is to reassure the woman that her baby appears to have no obvious structural abnormalities.

Recent data suggests that about 50% of significant abnormalities will be identified by a screening scan.

THIS PROTOCOL IS FOR USE BY THE FOLLOWING STAFF GROUPS :

- Qualified Sonographers or Midwife Sonographers who have a post graduate Certificate or Diploma in Ultrasound which has covered Obstetric ultrasound
- Consultant Radiologist or Obstetricians who have relevant ultrasound experience in Obstetric scanning, who hold an appropriate certification.

Lead Clinician(s)

Miss R Duckett
Dr R Johnson
Dr A Fabre-Gray

Consultant Obstetrician/Gynaecologist
Clinical Director of Radiology
Consultant Obstetrician

Approval Date 20th January 2023

Review Date 20th January 2026

This is the most current document and should be used until a revised version is in place

Key amendments to this guideline

Date	Amendment	By:
16.07.10	Extended without amendment	Miss R Imtiaz
14.12.10	Extended without amendment to await changes to service to reflect recommendations of NSC Best Practice	Mr S Agwu
06.12.11	Extended without amendment	Mr D Hill
15.06.12	Changes made according to the Fetal Anomaly Screening Programme – National Standards and Guidance for England (January 2010) Approved at Obstetric Governance Committee	A Morrison J Poultney D Adams J Ledger B Towler
28.05.15	Document extended to 1 st June as requested	L Thirumalaikumar
25.01.16	1) Amendments made in line with revised FASP national standards implemented April 2015, including introduction of extended cardiac 3 vessel trachea view to go live 21 st March 2016. 2) Clarification of timings for repeat scan if incomplete or suspected anomaly. 3) If RPD of >7mm at 20/40 then repeat at 32/40 and refer for consultant opinion and completion of a paediatric alert if >10mm.	R Duckett C. Stabler A. Morrison
05.05.16	1) Clarification in regards of renal dilatation pathway	R. Duckett A. Morrison
29.06.21	Guideline updated in line with amendment local guidance such as FGR and polyhydramnios. Document approved at July Maternity Governance meeting	A. Morrison
04/01/2023	Reviewed and updated in line with national guidelines	A Morrison

PROTOCOL FOR THE 18⁺⁰-20⁺⁶ WEEK ANOMALY SCAN

INTRODUCTION

This is a joint protocol developed by the Radiology and Obstetrics Directorates.

The purpose of this protocol is to provide an agreed and accepted standard for foetal anomaly scanning within Worcestershire Acute Hospitals NHS Trust

The fetal anomaly scan is to reassure the woman that her baby appears to have no obvious structural abnormalities. Ultrasound screening for fetal anomalies should be routinely offered, normally between 18 weeks 0 days and 20 weeks 6 days. Women should be informed of the limitations of routine ultrasound screening and that detection rates vary by the type of fetal anomaly (Appendix 1), the woman's body mass index and the position of the unborn baby at the time of the scan.

The objective of the ultrasound examination should be made as explicit as possible to women, they should be given information about the purpose and implications of the anomaly scan to enable them to make an informed choice as to whether or not to have the scan. The purpose of the scan is to identify fetal anomalies and plan subsequent management.

A national standard for a routine ultrasound anomaly scan was recommended by the Royal College of Gynaecologists (RCOG) Working Group. This provides parameters for sonographers, choice of options for women and provides purchasers with indications of how much screening could be accomplished within the available resources. The NHS Fetal Anomaly Screening Programme (2010, revised and implemented April 2015) Policy Position is for all Trusts to provide an 18-20+6 week fetal anomaly scan.

The ultrasound examination should be undertaken in an area/room designed for the purpose. Each fetal anomaly screening scan appointment slot/duration for a singleton pregnancy should be 30 minutes and the time doubled for a multiple pregnancy.

DETAILS OF GUIDELINE

Competencies required

Qualified Sonographers, Obstetricians or Midwife Sonographer who have a post graduate Certificate or Diploma in Ultrasound which has covered Obstetric ultrasound.

Patients covered

Pregnant women who wish to have a fetal anomaly scan.

PROTOCOL

It is understood that other conditions may be detected using this Ultrasound screening Tool, but because there are insufficient data to confidently predict the standard which should be achieved, 11 conditions have been set out. These 11 conditions were chosen because they were considered to be important, being fatal, associated with morbidity or requiring immediate postnatal support. They had detection rates which exceeded 50%

These conditions that should be screened for as a minimum from 2010 in the NHS for England are:

Conditions	Detection Rate (%)
Anencephaly	98
Open Spina Bifida	90
Cleft Lip	75
Diaphragmatic Hernia	60
Gastroschisis	98
Exomphalos	80
Serious Cardiac Abnormalities	50
Bilateral Renal Agenesis	84
Lethal Skeletal Dysplasia	60
Edwards Syndrome(Trisomy 18)	95
Patau's Syndrome(Trisomy13)	95

The 18⁺⁰- 20⁺⁶ Fetal Anomaly Scan:

(Please refer to Fetal Anomaly Screening Programme (FASP) National standards/handbook for England June 2015, Base Menu Appendix 1 and 2, page 28-35)

Images and Measurements Required.

- Head Circumference demonstrating HC measurement and measurement of the atrium of the lateral Ventricle.
- Suboccipito Bregmatic demonstrating measurement of the transcerebellar diameter
- Nuchal fold needs to be measured and imaged if appears large (6mm or >)
- Coronal view of lips with nasal tip
- Abdominal circumference AC measurement
- Femur length demonstrating FL measurement
- Sagittal view of the spine including sacrum and skin covering

(see Appendix 1, 18⁺⁰ to 20⁺⁶ fetal anomaly ultrasound scan base manual FASP National Standards handbook for England April 2015 p.28-29)

Determining Fetal Gender

There is no requirement to determine fetal sex within the Fetal Anomaly Screening Programme (FASP). There is no FASP Requirement to recall or re-book an appointment with the mother if the fetal sex cannot be identified simply owing to poor visualisation or difficult fetal position.

If the mother wishes to know the sex of the baby and the sonographer can see it they will tell the mother at the time of the scan. They will not write it down for the purposes of gender reveal or similar.

(Please refer to Society of Radiographers, 3rd Edition, January 2019, NHS Obstetric Ultrasound Examinations. Guidance on sale of Images, Fetal Sexing, Commercial Considerations and Requests to record.

Obstetric Pathways
WAHT-TP-094**POOR IMAGES**

All women should be offered a single further scan prior to the end of 23rd week of pregnancy to complete the screening examination if the image quality of the first examination is compromised by one of the following:

- Increased maternal body mass index(BMI)
- Uterine fibroids
- Abdominal Scarring
- Sub-optimal fetal position.

If the patient is being recalled because there is a possibility of abnormality, re-call appoint should be booked at 21/40 to allow fetal medicine to be able to see the patient by 21+6. This will help to avoid the need for fetocide in the event where abnormality was confirmed and patient decided to proceed with TOP (see Appendix 2).

Where an adequate assessment of the fetal anatomy remains compromised after the second scan, all women should be told that the screening is incomplete and this should be recorded in all formats.

PLACENTA

The placental site and the liquor volume are also assessed at the time of the fetal anomaly scan and any abnormality reported.

If the placenta appears to be abutting or covering the os at the fetal anomaly scan, re-scan should be arranged for 32/40 weeks of gestation. If unable to make definite diagnosis at 32/40 weeks transvaginal examination may be necessary.

ANOMALIES

When inconclusive or abnormal findings are identified on ultrasound examination, a second sonographer opinion may be required. Information must be communicated to the woman (and her partner if she wishes) by an appropriately trained and experienced individual and recorded within the electronic Badgernet pregnancy notes.

The woman should be referred to the fetal medicine team and appoints should be offered within 3 days of the scan. Please refer to the Referral following Identification of Fetal Anomaly (WHAT-OBS-076).

If an anomaly is detected during the anomaly scan pregnant women should be informed of the findings to enable them to make an informed choice as to whether they wish to continue with the pregnancy and or have amniocentesis if indicated or have a termination of pregnancy in certain cases.

The appearances listed below should be reported and the woman referred for further assessment and treatment as for any other suspected fetal anomaly.

1. Nuchal Fold (equal to 6mm or greater)
2. Ventriculomegaly~(atrium greater than 10mm)
3. Echogenic bowel(with density equivalent to bone)
4. Renal pelvic dilatation: (AP measurement greater than 7mm). Calyceal dilatation involvement should also be reported.
5. Small measurements compared to dating scan (less than 3rd centile)
6. Cleft lip
7. Talipes
8. Gastroschisis
9. Omphalocele
10. Neural tube defect

**Obstetric Pathways
WAHT-TP-094**

Please refer to the following guideline: Management of Suspected/Identified Fetal Anomalies.

Guidance for the professional

Some pregnancies affected by aneuploidy will have sonographic markers, which are listed above, but many karyotypically normal fetuses will also have these features.

If you are scanning at 20 weeks it is very important to know what screening has already been undertaken in your population. If your population has already been screened using maternal age alone, or in combination with nuchal translucency measurement or serum screening, 50 – 80% of affected cases will already have been identified, and it is therefore much less likely that a sonographic marker will be linked to aneuploidy, most typically 21, than in an unscreened population.

THE OPTIMAL STANDARD FOR MIDTRIMESTER ANOMALY SCAN

This would include the following:

- Head shape, Cavum septum pellucidum (CSP), ventricular atrium (VA), Cerebellum, Nuchal fold (NT)
- Coronal view of lips and nasal tip
- Visceral situs/laterality of heart, Four chamber view, Left outflow tract, Right outflow tract, or 3vessel view, 3 vessel trachea view
- Stomach and position, short intra-hepatic section of the umbilical vein, abdominal wall and cord insertion, Diaphragm, Kidneys, bladder
- Spine, skin covering
- Limbs upper and lower including femur, tibia and fibular in both legs, both feet, radius, ulna and humerus both arms and both hands
- Placental position and amniotic fluid assessment

See Appendix 1

In the event where the required structural views cannot be completed due to fetal position/Maternal BMI on 2nd attempt, the patients' should be informed that the screening is incomplete and this should be recorded in all formats.

FASP Guidelines on antenatal care recommends all 5 FASP cardiac views must be obtained as part of the routine anomaly scan, however FASP does not require them to be stored on PACS.

RECORD KEEPING

All scan results will be carefully documented and archived.

The 6 specific base menu (Appendix 1) sections should be identified a hard copy image and report should be recorded and appropriately stored in any of the following formats.

- Ultrasound Clinical Information system - CRIS
- Auditable Hospital Information system
- Ultrasound request/reports/images storage – CRIS and PACS
- Within the electronic Badgernet pregnancy notes

DNA

In the event of DNA – we are currently in the process of developing a robust DNA policy countywide. (Appendix 3)

**Obstetric Pathways
WAHT-TP-094**

MONITORING TOOL

To enable the trust to audit its results with respect to the direction of fetal abnormalities on an annual basis, results of fetal abnormalities will be held by the screening team.

REFERENCES

NHS Fetal Anomaly Screening Programme. 18⁺⁰-20⁺⁶ Weeks Fetal Anomaly Scan. National Standards and handbook for England (NHS FASP 2015)

Royal College of Obstetricians and Gynaecologists (2000) *Ultrasound Screening: "The 20 Week" Anomaly Scan*. July 2000

<http://www.rcog.org.uk/mainpages.asp?PageID=439#20week>.

Perinatal Institute. *Standard for Mid Trimester Fetal Anomaly Scan*

<http://www.perinate.org/ultrasound/midtrimester.htm>

NHS Fetal Anomaly Screening Programme 18⁺⁰ to 20⁺⁶ Fetal anomaly scan.

National standards and guidance for England 2012

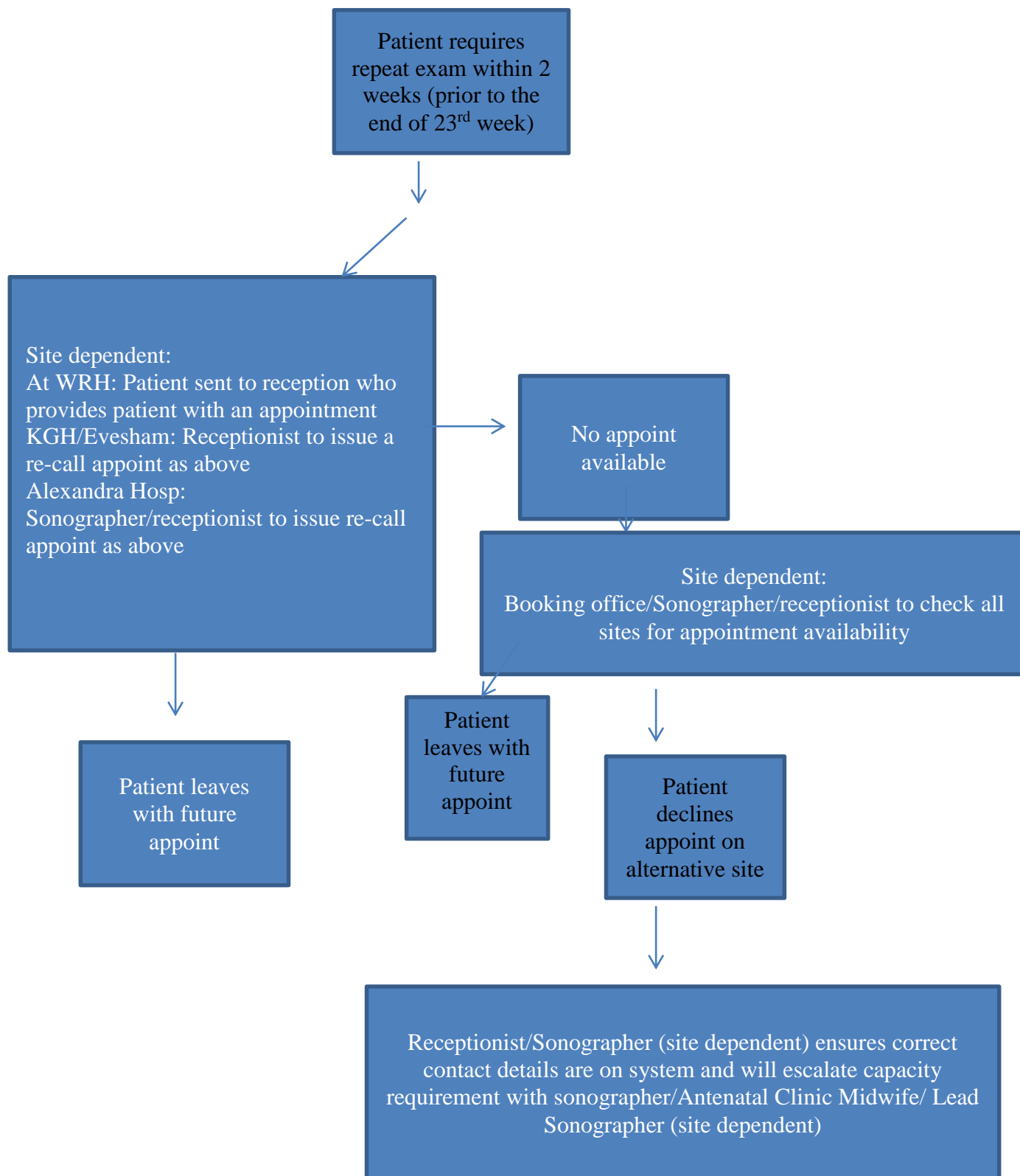
Appendix 1 – 18⁺⁰ to 20⁺⁶ FASP ultrasound scan base menu

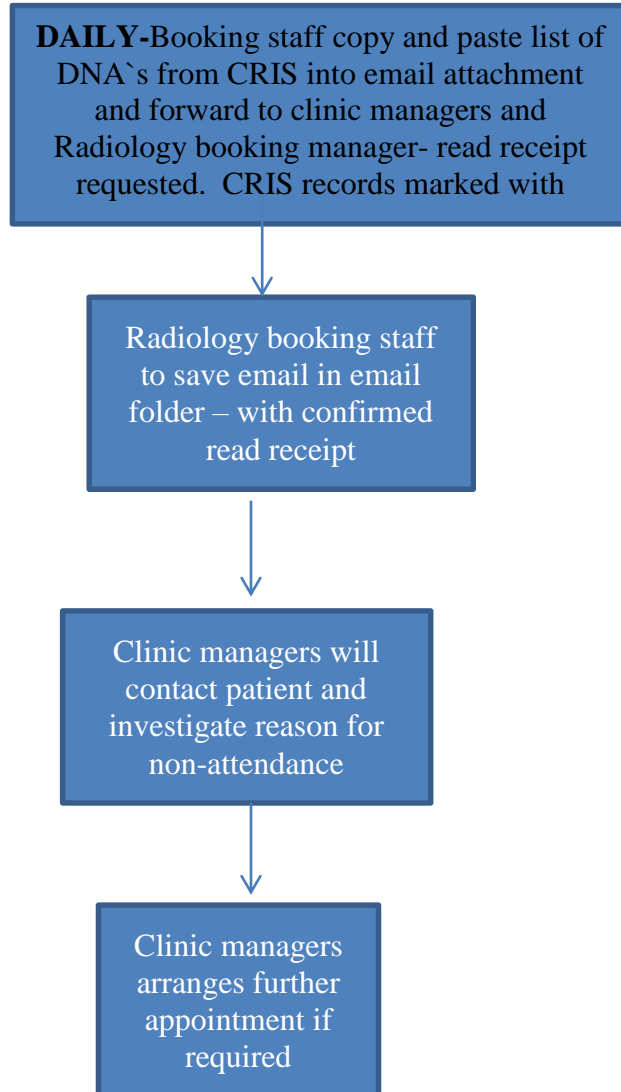
Structure/Area	Detail	Fetal Measurements*	Images/measurements to capture/archive
Head and neck • Skull • Brain • Neck	Head shape	*Head circumference (HC)	Yes, to include HC measurement, CSP, posterior horn and measurement of the ventricular atrium at the level of the glomus of the choroid plexus
	Cavum septum pellucidum (CSP)	Measurement not required	
	Ventricular Atrium (VA)	*Atrium of the lateral Ventricle	
	Cerebellum	*Transcerebellar diameter (TCD)	Yes, to include measurement of the TCD in the suboccipitobregmatic view
	Nuchal Fold (NF) Measure if appears large	Distance between the outer border of the occipital bone and the outer skin edge	Yes, if measurement ≥ 6mm
• Facial Features	Coronal view of lips & nasal tip	Measurement not required	Yes
• Lungs • Heart	Visceral situs/laterality of heart	Measurement not required	Annotate "LT" and "RT" on archived images to denote visceral situs/ laterality
	a) Four chamber view (FCV)		No
	b) Aorta (Ao) arising from left ventricle		No
	c) Pulmonary artery (PA) arising from right ventricle, or the 3 vessel view (3VV)		No
	d) 3 vessel and trachea view (3VT)		No

Appendix 1 – 18+0 to 20+6 FASP ultrasound scan base men

Structure/Area	Detail	Fetal Measurements*	Images/measurements to capture/archive
Abdominal content	Stomach & position	Measurement not required *Abdominal circumference (AC)	Yes
	Short intra-hepatic section of the umbilical vein (UV)		
	Abdominal wall and cord insertion		
	Diaphragm	Measurement not required	
	Kidneys Measure AP renal pelvis diameter if it appears large	Measurement not required unless renal pelvis AP diameter >7mm	Yes, if AP renal pelvis diameter measures >7mm
	Bladder	Measurement not required	
Spine	Vertebrae	Measurement not required	Yes, image either sagittal or coronal plane
<ul style="list-style-type: none"> • Cervical • Thoracic • Lumbar • Sacral 	Skin covering		
Limbs	Femur, tibia & fibula (both legs)	*Femur length	Yes, image and measure a single femur only
	Metatarsals (both feet)	Digit count not required	
	Radius, ulna, humerus (both arms)	Measurement not required	
	Metacarpals (both hands)	Digit count not required	
Uterine cavity	Placenta	According to local policy/protocol	
	<ul style="list-style-type: none"> • Uterine content Amniotic fluid	According to local policy/protocol	

Process for booking repeat anomaly scan





CONTRIBUTION LIST

Key individuals involved in developing the document

Name	Designation
David Hill Anna Fabre Grey	Chief Radiographer Fetal medicine lead/Obstetric Consultant
Miss R Duckett	Consultant Obstetrician
Mrs Swati Ghosh	Consultant Obstetrician/Gynaecologist
Mr Jon Hughes	Consultant Obstetrician/Gynaecologist
Mrs L Kumar	Consultant Obstetrician
D Adams	Ultrasonographer
N. Davidson	Ultrasonographer
J Ledger	Ultrasonographer
M Evans	Ultrasonographer
A Morrison	Midwife Sonographer
C Stabler	Lead Sonographer

Circulated to the following individuals for comments

Name	Designation
Anna Fabre Grey	Consultant Obstetrician
Miss R Duckett	Consultant Obstetrician/Gynaecologist
Mrs S Ghosh	Consultant Obstetrician/Gynaecologist
Emma Davis	Screening team Midwife/lead
Miss M Pathak	Consultant Obstetrician/Gynaecologist
Mr A Thomson	Clinical Director - Consultant Obstetrician/Gynaecologist
Margaret Stewart	Matron OP-Community

Circulated to the chair of the following committees/groups for comments/approval

Name	Directorate / Department
	Maternity Governance Meeting